


Mild (previously **Category 1**)

lesion(s) on 1 arm or body

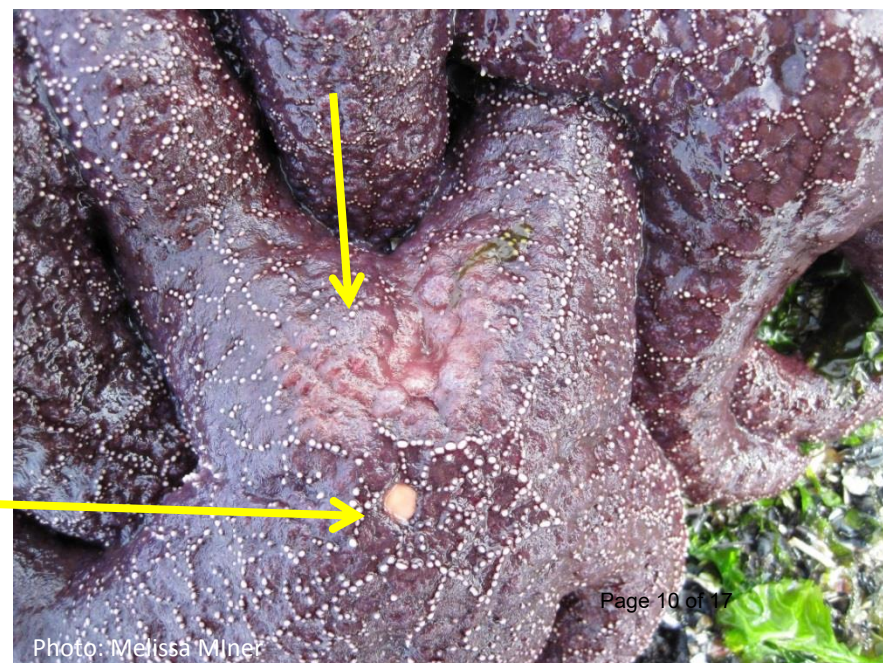
Tissue degradation in some of these photos may be the result of multiple lesions merging, but it is restricted to a single arm, or single location on the oral disk.



Mild (previously Category 1)



NOT a lesion
(madreporite)



Mild (previously **Category 2**)

lesions on 2 arms or 1 arm and body and/or
deteriorating arm(s)




Photo: Melissa Miner

Arm starting to separate




Photo: Melissa Miner

Tissue deteriorating on 2 arms

Severe (previously Category 3)

lesions on most of body and/or 1-2 missing arms

Missing 1 arm

tissue deterioration
on 2nd arm




Photo: Laura Anderson

©2018 by University of California, Santa Cruz. All rights reserved.




Photo: Melissa Miner

Missing 1 arm



Photo: Nathaniel Fletcher

Severe (previously Category 3)



Missing tips of 2 arms, lesion on 3rd

Severe (previously Category 4)

severe tissue deterioration/death
and/or ≥ 3 missing arms



Severe (previously Category 4)



Photo: Dennis Paulson

Internal organs emerging from lesions



Photo: Melissa Miner



Spawning (all healthy/Category 0)



Spawning (all healthy/Category 0)

